

Minimally Invasive Treatments of Hemorrhoidal Disease

Ahmad Izadpanah^{1,*}

¹ Colorectal Research Center, Shiraz University of Medical Sciences, Shiraz, IR Iran

*Corresponding author: Ahmad Izadpanah, Colorectal Research Center, Shiraz University of Medical Sciences, Shiraz, IR Iran. Tel.: +98-7112306972, Fax: +98-7112330724, E-mail: iza-dpana@sums.ac.ir

Received: Jun 25, 2013; Revised: Jun 27, 2013; Accepted: July 01, 2013

Context: Minimally invasive procedures are used for treatment of nonresponsive hemorrhoids to conservative therapy. These OPD (Out-Patient Department) procedures are effective to eradicate the hemorrhoid symptoms with minimal postoperative pain and complications.

Evidence Acquisition: In this review, data base of PubMed, and MEDLINE were searched with time limitation(2002- 2012). Recent articles in English journals were reviewed to evaluate and compare these minimally invasive procedures including Rubber band ligation (RBL), Infrared coagulation (IRC), Direct current Electrotherapy (DCE), and Sclerotherapy.

Results: Upon the articles, 881 were treated with RBL, 454 with IRC, 1203 with DCE, and 2372 with sclerotherapy. Postoperative pain, which is a common complication of hemorrhoidectomy, was 3-25% in RBL, 2.13-4.3% in DCE, and 1.8-7% in sclerotherapy. Pain was mild to moderate and rarely needed analgesic. Postoperative rectal bleeding was seen in 1.26-32.4% of patients treated with RBL. Recurrence of preoperative symptoms was 1.9-39% for RBL, 6.9-21% for sclerotherapy, and 2.9-3% for DCE. Postoperative complications were minor in all procedures and for sclerotherapy it was seen in 6.9-21% of patients. Success rate was 69.4-96.4% in RBL, 80% in IRC, 89.3-99.7% in sclerotherapy, and 98.2% in DCE. Patient's satisfaction was 98% for DCE versus 99% for RBL and IRC. Operation time for each tag of hemorrhoid was 4.5-10 minutes for DCE, regarding different amplitudes of current and degrees of hemorrhoid, and 13 minutes for sclerotherapy and not reported for other methods.

Conclusions: Minimally invasive procedures are used depending on surgeon's experience and preference. These modalities are comparable from different aspects. The cost of treatment and availability of equipment may affect the choice of modality. All of these techniques could be used in patients resulting in maximum success rate and minimum complications.

Keywords: Minimally Invasive; Hemorrhoids; Treatment

1. Context

Symptomatic hemorrhoids irresponsive to conservative therapy may be treated with minimally invasive procedures. Hemorrhoidectomy which was the gold standard for treatment of hemorrhoids (1) should be performed in operating room under anesthesia and is associated with postoperative severe pain (2-4). Minimally invasive techniques including Rubber Band Ligation (RBL), Infrared Coagulation (IRC), sclerotherapy, and Direct Current Electrotherapy (DCE) used in treatment of hemorrhoids are preferred especially for internal second and third degree hemorrhoids. No need for preoperative enema and anesthesia for these OPD minimally invasive procedures are important advantages.

These modalities have less postoperative pain, complications and time off work which causes more acceptance among patients (2, 5, 6). In these modalities, anal canal mucosa is not damaged except for RBL. Also fibrosis fixes

mucosa to layers beneath and shrinks the vascular plexus. Reviewing articles, minimally invasive techniques have been compared in pairs but no study has ever contrasted these altogether. Thus, we assessed recent articles from English Medical Journals to investigate the effectiveness and complications of different minimally invasive procedures in our review article.

2. Evidence Acquisition

In this review, data base of PubMed, and MEDLINE were searched with time limitation(2002- 2012). Recent articles in English journals were reviewed to evaluate and compare these minimally invasive procedures. The key words which been used in the search are: "Hemorrhoids" OR "Hemorrhoid treatment" OR "External Hemorrhoids" and each of them with the following key words with AND, "Rubber band ligation (RBL)", "Infrared coagulation (IRC)", "Direct current Electrotherapy (DCE)", and "Sclerotherapy".

Implication for health policy/practice/research/medical education:

This article is a review of Minimally Invasive Treatments of Hemorrhoidal Disease. It is helpful for gastroenterologist colorectal and general surgeons.

Copyright © 2013, Colorectal Research Center and Health Policy Research Center of Shiraz University of Medical Sciences; Licensee Safnek Ltd. This is an Open Access article distributed under the terms of the Creative Commons Attribution License (<http://creativecommons.org/licenses/by/3.0>), which permits unrestricted use, distribution, and reproduction in any medium, provided the original work is properly cited.

2.1. Rubber Band Ligation (RBL)

In this technique, a part of the hemorrhoid is squeezed by a Rubber band hard enough to cause relative ischemia to the tissue contained within (Figure 1), which would then slough (2, 6 - 8). Each rubber band grasps a small segment of hemorrhoid tissue; therefore, it is needed for several bands to treat each hemorrhoidal tag. Rubber bands have to be placed proximal to the dentate line; otherwise, sever pain is inevitable. Grasping the sphincter muscle results in sever spasm and subsequent pain. Tissue slough may proceed sever bleeding which requires suturing.

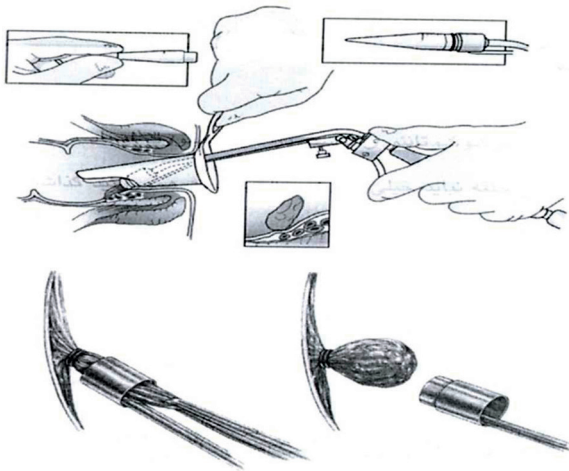


Figure 1. Instruments and Method for Doing RBL. A Rubber Band Is Fixed Around a Piece of Hemorrhoid Tissue (27).

2.2. Sclerotherapy

In this procedure, a sclerosing agent like aluminium potassium sulfate and tannic acid (ALTA) (5, 9), is injected into the hemorrhoid tissue which creates fibrosis and fixation of the hemorrhoid mucosa to the underlining sphincter muscle (5, 8 - 10). Sclerosant is usually injected into each hemorrhoid (Figure 2).

2.3. Direct Current Electro therapy (DCE)

In this technique, the negative electrode is directed into the base of hemorrhoid (Figure 3), and the positive electrode is placed under patient's buttocks to create the shortest electrical pathway (11 - 13). A direct current is delivered at increasing amperage up to 16 mAmp in patients without general anesthesia and 30 mAmp with general anesthesia (11, 12). In patients with no anesthesia, amperage more and faster than abovementioned causes pain and microshock respectively (11, 12). The time course to treat hemorrhoid depends on the applied amperage. To illustrate, grade I hemorrhoids need

16 mAmp for 10 minutes, while may be treated in 2.5 minutes with 30 mAmp. The negative electrode should be placed proximal to the dentate line. It seems that direct current causes electrolysis and then fibrosis of the hemorrhoid plexus.

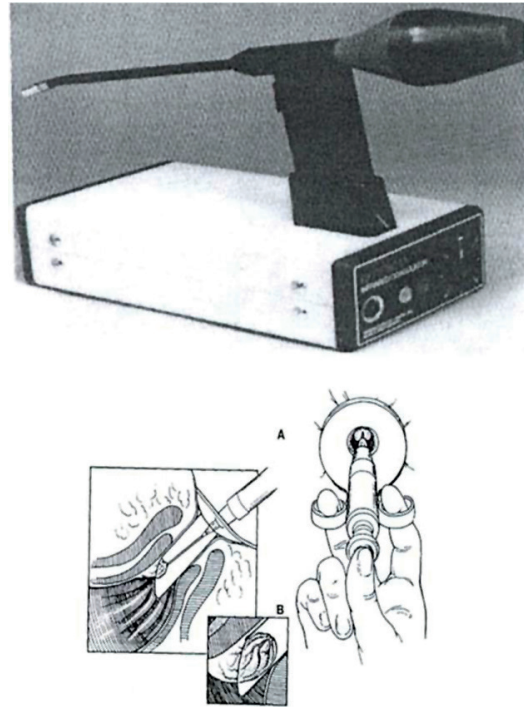


Figure 2. Injection of Sclerosant Agent Into Hemorrhoid (27)

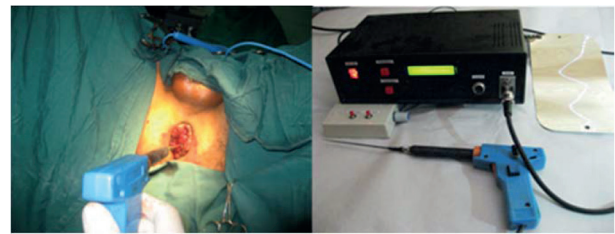


Figure 3. Apparatus and How to Apply in DCE Method, 16 to 30 mAmp Direct Current Is applied to Hemorrhoid Plexus; Plate Which Is the Positive Electrode Is Fixed to the Patient's Buttock (12).

2.4. Infrared coagulation (IRC)

In this procedure infrared radiation coagulates proteins and creates fibrosis to eliminate the hemorrhoid in two weeks (14, 15). The applicator tip is placed at the apex of hemorrhoid to yield a 4 mm² focus of coagulation with a 2.5 mm depth (Figure 4). Radiation close to the dentate line or more excess than indicated causes pain or bleeding respectively.

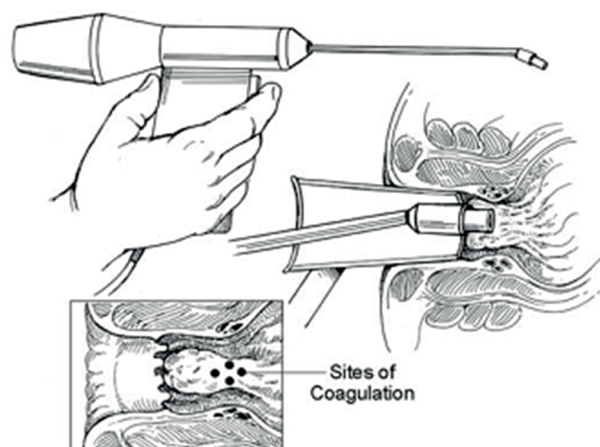


Figure 4. Apparatus and the Method Used for IRC (27)

We searched PubMed for English articles on treatment of hemorrhoid by minimally invasive techniques published in the recent 20 years. We extracted data from articles presented (Table 1) to compare these procedures regarding their effectiveness and complication.

3. Results

As shown in Table 1, the number of adult patients of either sex treated was 881 for RBL (16 - 21), 454 for IRC (18 , 22 - 24), 1203 for DCE (11 - 13 , 25), and 2372 for sclerotherapy (5 , 9 , 10 , 26). Posttreatment pain, also a common complication of hemorrhoidectomy, was 3-25% in RBL, 2.13-4.3% in DCE, and 1.8-7% in sclerotherapy. This was mild to moderate and rarely needed oral analgesic. Post treatment rectal bleeding was seen in 1.26-32.4% of patients treated with RBL. Recurrence of preoperative symptoms during follow-up was 1.9-39% for RBL, 2.9-3% for DCE, and 6.9-21% for sclerotherapy. Posttreatment complications were minor in all procedures, and for sclerotherapy it was seen in 6.9-21% of patients (5). Success rate was 69.4-96.4% in RBL, 89.3-99.7% in sclerotherapy, 80% in IRC, and 98.2% in DCE (4 , 5 , 9 - 11 , 13 - 24 , 26). Patient ' s satisfaction was 99% for RBL and IRC versus 98% for DCE. Operation time per tag of hemorrhoid regarding different amplitudes of currency and degrees of hemorrhoid was 4.5-10 minutes for DCE (11 , 12 , 14), and 13 minutes for sclerotherapy (10), and not reported for other methods.

Table 2. Results of Comparing Items in Reviewed Articles About Minimally Invasive Modalities

Variables	RBL	IRC	DCE	Sclerotherapy
Patients, No.	88	454	1204	2374
Pain mild/moderate, %	0.3 - 25	2.13 - 4.3	8 - 15	1.8 - 7
Bleeding, %	1.26 - 32.4	4.3	2.5 - 3	10.7
Recurrence, %	1.9 - 39	20	2.9 - 3	3.6 - 10.7
Operation time	-	-	4.5 - 10 m/tag*	13 m*
Return to work, day	1	1	1 - 2	1
Post op complication	Minor		Minor	6.9 (21)
Success rate, %	69.4 - 99	79.5 - 99	97 - 97.1	96 - 96.4
Patients satisfaction, %	99	99	98	

* Abbreviations: m/tag, minutes/tag hemorrhoid; m, minutes

4. Conclusion

Hemorrhoidectomy, as the gold standard in treatment of hemorrhoid, is associated with sever postoperative pain and sometimes with profuse bleeding as such the patient has to be returned back to the operating room. It is associated with more operating time, too. Patients for hemorrhoidectomy should undergo general anesthesia at hospital and bear prolonged delay in returning to normal activities for up to a month. Thus, minimally invasive procedures have been widely adopted since years ago holding both advantages and disadvantages. None of these techniques has been proven to be favored over others. In RBL, used for first- and second- rarely third- degree internal hemorrhoids, a small segment of hemorrhoid is placed in a rubber band, so for one hemorrhoid tag several rubber bands are used in differ-

ent parts (16, 17). This means several visits for full treatment. Postoperation pain, resulting from placement of band less than two cm proximal from the dentate line or grasping the sphincter muscle, had surgeons to remove the rubber band. Sloughing of mucosa contained within the band may cause bleeding which needs surgical intervention. Serious infection of site is also reported (18). In IRC, limitation of employing infrared radiation for an area of maximum 3-4 mm necessitates treatment for different parts of one hemorrhoid (22). This together with the relatively high recurrence has made this procedure unfavorable to surgeons. Injection sclerotherapy may change anal sphincter function, induce postoperative infection, make mucosa slough creating long-term ulcer (5, 10). These have eliminated the use of this technique in most centers.

Table 1. Reviewed Articles on Minimally Invasive Methods for Hemorrhoid Diseases in the Last 20 Years

Author(s), Year	Study Design	Modality of treatment	No. of patients (Success rate, %)	Post-op pain, %	Post-op bleeding (continuous bleeding), %	Recurrence, %	Return time to work	Satisfaction of patient, % (or score)	Modality Facility	Operation Time, minutes/tag of hemorrhoid	Complications
Norman DA, 1989, 16m Amp	Prospective	DCE	120						Safe, pain less, effective	10	
Wright RA, 1991		CE	16								
Izadpanah A, 2004, 30m Amp	Prospective	CE	931 (97.1)	8, One day	2.5	2.9%	2 days	98	Safe, effective, No complication	4.5-7	
Izadpanah A, 2005, 30m Amp	Prospective	CE	136 (91)	15, 2-7 days	3	3%	1-2	98	Safe effective	6.1	short operative duration, less pain
Filingeri, 2012	Prospective	RBL	360 (69.4)	2.08 ± 1.1 (2.69 ± 1.12)		30.6%		6.61 ± 2.35	comfort		
Yano T, 2012	Prospective	Sclero-therapy (ALTA)	37	2.13 ± 1.26 (2.38 ± 1.18)		20.5%		6.72 ± 2.28			
Jahanshahi A, 2012	prospective	Diode laser, IRC	341								3.51%
Miyamoto H. Yano To, 2012		Sclero-therapy	28 (89.3%) 57 (53%)		10.7% 21%	10.7% 42%		Useful, less invasive		21% (7% real)	
Hachiro Y, 2011		Sclero-therapy	121 48 706 5 (96.4-99.7%)			3.6% 6.3%		Simple safe		6.9%	
Tokunaga Yaki-hiko, 2010		Sclero-therapy	784 (96)	1.8		4%	Out patient			13 minutes	
Sekowskam, 2011		RBL	474 (68.5)	Score of pain: 0.3 (95%)		11%	3.8 days	Tolerable			
Marques CF, 2006		IRC	47	29.6%	4.3%		99%	Effective			Minor
		RBL	47	19.2%	32.4%		99%				
Wehrmann T, 2004	Prospective	RBL	100	25%, Severe 7%	3.5%	20%					Minor
Fukuda A, 2004	Prospective	RBL	82 (89)	1.0.3	1.26	1.94		Safe effective			
Vrzgula A, 2001	Prospective	RBL	77 (91)		8%	39%	1 day				
Gupta PJ, 2007	Prospective	IRC	300					Easy Safe Painless Quick			Pruritus defecation discomfort anal discharge
Poen AC, 2000	Prospective	RBL IRC	65 (97%) 68 (92%)	More severe than IRC		18%, In time of F.U. 20%		Effective			

In direct-current electrotherapy (DCE), the low amperage (16 mA) and easy technique without the need to inject sclerosant introduce it as a safe procedure (3, 11). One drawback of this technique is the time course required to treat each hemorrhoidal tag (11) which is usually up to 30 minutes (2.5 times; each time 10 minutes). However, the advantage of not sloughing of mucosa and not adverting effect on anal sphincter muscle, encourage surgeons to welcome it.

In further studies using DCE, increasing amperage up to 30 mA (12, 14), has decreased time course of procedure to less than five minutes for each hemorrhoid. However, applying more than 16 mA necessitates regional, spinal or general anesthesia (12, 14). As shown in Table 2 minimally invasive techniques have few comparable complications.

Postoperative pain is reported by a small percentage of patients undergoing any technique except for RBL for up to 25% of patients. Of course, degree of pain is mild to moderate for all of these procedures not making one preferable to the other ones. Postoperative bleeding has also been reported in a small number of patients treated by any procedure, while was observed up to 32% for RBL (18), and 10% for sclerotherapy in some studies. Recurrence rate during follow up time was up to 39% for RBL, 20% for IRC, and 10.7% for sclerotherapy (26), where it was 2.5% - 3% for DCE using 30 mA (12, 14). The time course required to treat was comparable for all techniques almost the same for DCE using 30 mA, RBL and IRC but the longest for sclerotherapy with about 13 minutes (10). Almost all patients were treated in OPD setting and as a consequence returned back to normal activities within a day. Postoperative complication was minimal while success rate was significant in all. Although, some studies have reported success rates of 69.4% (22) and 79.5% (24) for RBL and IRC correspondingly, but overall success rate for all procedures was acceptable and up to 99% (5, 9-14, 16-24, 26). Patient's satisfaction in RBL, IRC and DCE was 98% - 99% (12, 14, 18). Postoperative complication following sclerotherapy was more than other methods resulting in less preference among physicians.

Considering limitations of this review article, minimally invasive procedures which are used depending on surgeon's experience and preference are comparable from different aspects, while availability of equipment and cost of treatment may affect choice of modality. One cannot prefer one modality over other types. It seems that all of these techniques have the opportunity to be used in patients resulting in maximum success and minimum complications.

Acknowledgements

The author would like to thank Colorectal research center Shiraz University of Medical Sciences for their cooperation.

Financial Disclosure

No financial interest to report.

Funding/Support

The work was supported by colorectal research center of Shiraz University of Medical Sciences.

References

1. MacRae HM, McLeod RS. Comparison of hemorrhoidal treatment modalities. A meta-analysis. *Dis Colon Rectum*. 1995;**38**(7):687-94.
2. Shanmugam V, Thaha MA, Rabindranath KS, Campbell KL, Steele RJ, Loudon MA. Systematic review of randomized trials comparing rubber band ligation with excisional haemorrhoidectomy. *Br J Surg*. 2005;**92**(12):1481-7.
3. Diurni M, Di Giuseppe M. Hemorrhoidectomy in day surgery. *Int J Surg*. 2008;**6** Suppl 1:S53-5.
4. Shanmugam V, Thaha MA, Rabindranath KS, Campbell KL, Steele RJ, Loudon MA. Rubber band ligation versus excisional haemorrhoidectomy for hemorrhoids. *Cochrane Database Syst Rev*. 2005;(3):CD005034.
5. Hachiro Y, Kunimoto M, Abe T, Kitada M, Ebisawa Y. Aluminum potassium sulfate and tannic acid (ALTA) injection as the mainstay of treatment for internal hemorrhoids. *Surg Today*. 2011;**41**(6):806-9.
6. Ohning GV, Machicado GA, Jensen DM. Definitive therapy for internal hemorrhoids—new opportunities and options. *Rev Gastroenterol Disord*. 2009;**9**(1):16-26.
7. Iyer VS, Shrier I, Gordon PH. Long-term outcome of rubber band ligation for symptomatic primary and recurrent internal hemorrhoids. *Dis Colon Rectum*. 2004;**47**(8):1364-70.
8. Chew SS, Marshall L, Kalish L, Tham J, Grieve DA, Douglas PR, et al. Short-term and long-term results of combined sclerotherapy and rubber band ligation of hemorrhoids and mucosal prolapse. *Dis Colon Rectum*. 2003;**46**(9):1232-7.
9. Yano T, Nogaki T, Asano M, Tanaka S, Kawakami K, Matsuda Y. Outcomes of case-matched injection sclerotherapy with a new agent for hemorrhoids in patients treated with or without blood thinners. *Surg Today*. 2012.
10. Tokunaga Y, Sasaki H, Saito T. Evaluation of sclerotherapy with a new sclerosing agent and stapled hemorrhoidectomy for prolapsing internal hemorrhoids: retrospective comparison with hemorrhoidectomy. *Dig Surg*. 2010;**27**(6):469-72.
11. Norman DA, Newton R, Nicholas GV. Direct current electrotherapy of internal hemorrhoids: an effective, safe, and painless outpatient approach. *Am J Gastroenterol*. 1989;**84**(5):482-7.
12. Izadpanah A, Hosseini SV, Mehrabani D, Bananzadeh A. Assessment of electrotherapy in treatment of hemorrhoids in Southern Iran. *Saudi Med J*. Saudi Arabia: 2004. p. 1896-9.
13. Wright RA, Kranz KR, Kirby SL. A prospective crossover trial of direct current electrotherapy in symptomatic hemorrhoidal disease. *Gastrointest Endosc*. 1991;**37**(6):621-3.
14. Izadpanah A, Hosseini SV. Comparison of electrotherapy of hemorrhoids and Ferguson hemorrhoidectomy in a randomized prospective study. *Int J Surg*. England: 2005. p. 258-62.
15. Filingeri V, Angelico R, Bellini MI, Manuelli M, Sforza D. Ambulatory therapy with combined hemorrhoidal radiocoagulation. *Eur Rev Med Pharmacol Sci*. 2013;**17**(1):130-3.
16. Filingeri V, Angelico R, Bellini MI, Manuelli M, Sforza D. Prospective randomised comparison of rubber band ligation (RBL) and combined hemorrhoidal radiocoagulation (CHR). *Eur Rev Med Pharmacol Sci*. 2012;**16**(2):224-9.
17. Sekowska M, Koscinski T, Wierzbicki T, Hermann J, Drews M. Treatment of the hemorrhoids and anal mucosal prolapse using elastic band ligation—early and long term results. *Pol Przegl Chir*. 2011;**83**(12):654-61.
18. Marques CF, Nahas SC, Nahas CS, Habr-Gama A, Kiss DR, Sobrado CWJr. Early results of the treatment of internal hemorrhoid dis-

- ease by infrared coagulation and elastic banding: a prospective randomized cross-over trial. *Tech Coloproctol.* 2006;**10**(4):312-7.
19. Wehrmann T, Riphaut A, Feinstein J, Stergiou N. Hemorrhoidal elastic band ligation with flexible videoendoscopes: a prospective, randomized comparison with the conventional technique that uses rigid proctoscopes. *Gastrointest Endosc.* 2004;**60**(2):191-5.
 20. Fukuda A, Kajiyama T, Arakawa H, Kishimoto H, Someda H, Sakai M, et al. Retroflexed endoscopic multiple band ligation of symptomatic internal hemorrhoids. *Gastrointest Endosc.* 2004;**59**(3):380-4.
 21. Vrzgula A, Bober J, Valko M, Franko J, Lukacova Z, Seginak V. [Rubber band ligation of hemorrhoids in ambulatory care]. *Rozhl Chir.* 2001;**80**(7):353-5.
 22. Jahanshahi A, Mashhadizadeh E, Sarmast MH. Diode laser for treatment of symptomatic hemorrhoid: a short term clinical result of a mini invasive treatment, and one year follow up. *Pol Przegl Chir.* 2012;**84**(7):329-32.
 23. Gupta PJ. Infra red photocoagulation of early grades of hemorrhoids-5-year follow-up study. *Bratisl Lek Listy.* 2007;**108**(4-5):223-6.
 24. Poen AC, Felt-Bersma RJ, Cuesta MA, Deville W, Meuwissen SG. A randomized controlled trial of rubber band ligation versus infra-red coagulation in the treatment of internal haemorrhoids. *Eur J Gastroenterol Hepatol.* 2000;**12**(5):535-9.
 25. Izadpanah A, Hosseini SV. Comparison of electrotherapy of hemorrhoids and Ferguson hemorrhoidectomy in a randomized prospective study. *Int J Surg.* 2005;**3**(4):258-62.
 26. Miyamoto H, Asanoma M, Shimada M. ALTA injection sclerosing therapy: non-excisional treatment of internal hemorrhoids. *Hepatogastroenterology.* 2012;**59**(113):77-80.
 27. Corman ML. *Colon and Rectal Surgery.* 5th ed. Philadelphia: Lippincott Williams & Wilkins; 2005. Chapter 8.